



ID7000™ Spectral Cell Analyzer

Learn how the **ID7000 Spectral Cell Analyzer** has empowered **biomedical research**

[Download Publications List](#)

SONY

REVIEW

New-onset autoimmune phenomena post-COVID-19 vaccination

Yue Chen^{1,2} | Zhiwei Xu³ | Peng Wang⁴ | Xiao-Mei Li⁵ | Zong-Wen Shuai⁶ | Dong-Qing Ye^{1,2} | Hai-Feng Pan^{1,2} 

¹Department of Epidemiology and Biostatistics, School of Public Health, Anhui Medical University, Hefei, China

²Inflammation and Immune Mediated Diseases Laboratory of Anhui Province, Hefei, China

³School of Public Health, Faculty of Medicine, University of Queensland, Brisbane, Qld, Australia

⁴Teaching Center of Preventive Medicine, School of Public Health, Anhui Medical University, Hefei, China

⁵Department of Rheumatology, The First Affiliated Hospital of University of Science and Technology of China, Hefei, China

⁶Department of Rheumatology and Immunology, The First Affiliated Hospital of Anhui Medical University, Hefei, China

Correspondence

Dong-Qing Ye and Hai-Feng Pan,
Department of Epidemiology and
Biostatistics, School of Public Health,
Anhui Medical University, 81 Mei-Shan
Road, Hefei, Anhui, 230032, China.
Email: ydqahmu@126.com (D.Q.Y.);
panhaifeng1982@sina.com (H.F.P.)

Senior author: Hai-Feng Pan.

Funding information

This work was supported by the
National Natural Science Foundation
of China (81872687), Anhui Provincial
Natural Science Foundation
(2108085Y26, 2108085QH361) and
Research Fund of Anhui Institute of
Translational Medicine (2021zhyx-B04).

Abstract

Coronavirus disease 2019 (COVID-19) pandemic caused by severe acute respiratory syndrome coronavirus 2 (SARS-CoV-2) has led to an unprecedented setback for global economy and health. Vaccination is one of the most effective interventions to substantially reduce severe disease and death due to SARS-CoV-2 infection. Vaccination programmes are being rolled out globally, but most of these vaccines have been approved without extensive studies on their side-effects and efficacy. Recently, new-onset autoimmune phenomena after COVID-19 vaccination have been reported increasingly (e.g. immune thrombotic thrombocytopenia, autoimmune liver diseases, Guillain-Barré syndrome, IgA nephropathy, rheumatoid arthritis and systemic lupus erythematosus). Molecular mimicry, the production of particular autoantibodies and the role of certain vaccine adjuvants seem to be substantial contributors to autoimmune phenomena. However, whether the association between COVID-19 vaccine and autoimmune manifestations is coincidental or causal remains to be elucidated. Here, we summarize the emerging evidence about autoimmune manifestations occurring in response to certain COVID-19 vaccines. Although information pertaining to the risk of autoimmune disease as a consequence of vaccination is controversial, we merely propose our current understanding of autoimmune manifestations associated with COVID-19 vaccine. In fact, we do not aim to disavow the overwhelming benefits of mass COVID-19 vaccination in preventing COVID-19 morbidity and mortality. These reports could help guide clinical assessment and management of autoimmune manifestations after COVID-19 vaccination.

Abbreviations: ACE2, angiotensin-converting enzyme inhibitor 2; AIH, autoimmune hepatitis; ALP, alkaline phosphatase; ALT, alanine aminotransferase; ANA, antinuclear antibody; ARDS, acute respiratory distress syndrome; AST, aspartate aminotransferase; COVID-19, coronavirus disease 2019; CT, computed tomography; CVST, cerebral venous sinus thrombosis; GBS, Guillain-Barré syndrome; HIT, heparin-induced thrombocytopenia; IL-6, interleukin-6; ITP, immune thrombocytopenic purpura; IVIg, intravenous immunoglobulin; NF-κB, nuclear factor kappa B; NLRP3, NLR pyrin domain containing 3; PBC, primary biliary cholangitis; PEG, polyethylene glycol; PF4, platelet factor 4; PSC, primary sclerosing cholangitis; SARS-CoV-2, severe acute respiratory syndrome coronavirus 2; SLE, systemic lupus erythematosus; SVT, splanchnic vein thrombosis; TLRs, Toll-like receptors; VITT, vaccine-induced immune thrombotic thrombocytopenia.

KEYWORDS

adverse events, autoimmune diseases, COVID-19, SARS-CoV-2, vaccines

INTRODUCTION

At the end of 2019, coronavirus disease 2019 (COVID-19) was first reported in Wuhan, China, triggered by severe acute respiratory syndrome coronavirus 2 (SARS-CoV-2), and has swiftly spread worldwide. As of 6 September 2021, there have been 4.57 million confirmed deaths and 221 million confirmed cases of COVID-19 based on the COVID-19 Open Datasets by the Center for Systems Science and Engineering at Johns Hopkins University [1]. COVID-19 is characterized by a wide range of presentations, from asymptomatic or flulike illness causing fever, dry cough, fatigue, headache, loss of taste and smell to severe pneumonia, leading to an acute respiratory distress syndrome (ARDS), with subsequent respiratory failure requiring mechanical ventilation [2–4]. Cytokine storm caused by SARS-CoV-2 is involved in the major mechanism by inducing the production of pro-inflammatory cytokines and chemokines such as IL-1 β , IL-6, IL-18, TNF- α and macrophage inflammatory proteins [5], ultimately leading to respiratory failure and death due to multi-organ failure [6, 7]. In addition, previous studies indicated that COVID-19 appears to be a risk factor for thrombosis through endothelial dysfunction, platelet activation and abnormal blood flow described by Virchow, and the same scenario has been found in patients with COVID-19 during pregnancy [8–10]. To date, treatments for COVID-19 are mainly targeted symptomatic treatment and supportive therapy. Currently, one of the most effective strategies for mitigating COVID-19 pandemic is global vaccination that can create an immune barrier among population to attenuate the speed and scope of SARS-CoV-2 transmission. As of 6 September 2021, 40.4% of the population worldwide have been given at least one dose of a COVID-19 vaccine, and 5.45 billion doses have been administered globally [11]. The two most common COVID-19 vaccine platforms currently in use, including mRNA (i.e. Pfizer-BioNTech and Moderna) and adenovirus vector (i.e. Johnson & Johnson and AstraZeneca), elicit robust humoral responses and have shown safety in the majority of populations vaccinated [12].

However, as vaccination programmes are being rolled out globally, many COVID-19 vaccine-related side-effects have been recently reported [13, 14], ranging from mild local symptoms (e.g. pain at the injection site) to systemic symptoms (e.g. fever and/or headache) [15]. Localized pain, fatigue, headache and muscle ache are the most

prevalent adverse effects in patients with autoimmune and inflammatory rheumatic diseases following six COVID-19 vaccines [16]. Previous studies indicated that human papillomavirus, hepatitis B and influenza vaccines may trigger the onset or exacerbations of autoimmune diseases by molecular mimicry inducing autoimmunity [17–19]. A growing body of evidence has indicated that myocarditis [20], vaccine-induced immune thrombotic thrombocytopenia (VITT) [21, 22], IgA vasculitis [23] and autoimmune diseases, etc., may be potential consequence of COVID-19 vaccines. Of note, side-effects vary considerably in line with the recipient's age and sex, with more severe effects in women than in men and in younger people than in the elderly [24]. However, whether the association between COVID-19 vaccine and autoimmune manifestations is coincidental or causal remains to be elucidated.

Given the emerging evidence between certain COVID-19 vaccines and autoimmune disease, the risk of autoimmune disease triggered by immunization has sparked public concern. Here, we discuss the major types of COVID-19 vaccines currently in use and their mechanisms of action. Then, we postulate the plausible mechanism of immune activation triggered by COVID-19 vaccine. Finally, we summarize a set of cases presenting with autoimmune manifestations occurring in response to COVID-19 vaccines, including VITT, autoimmune liver diseases, Guillain-Barré syndrome (GBS), IgA nephropathy and other autoimmune manifestations. These reports could help provide guidance for the clinical assessment and management of autoimmune manifestations following COVID-19 vaccination.

SEARCH STRATEGY

The MEDLINE/PubMed, Embase and Scopus electronic databases were used to search for literature on COVID-19 vaccination and new-onset autoimmune phenomena published up to 31 October 2021. Both Mesh and relevant free-text terms were used as follows: ("COVID-19 Vaccine*" OR "SARS-CoV-2 vaccine*") AND ("autoimmune diseases" OR "autoimmunity" OR "autoimmune hepatitis" OR "thrombocytopenic idiopathic purpura" OR "Guillain-Barre Syndrome" OR "systemic lupus erythematosus" OR "IgA glomerulonephritis" OR "vaccine induced thrombotic thrombocytopenia"). Table 1 details the terms used in the literature search.

COVID-19 VACCINES AND THE MECHANISMS OF IMMUNE ACTIVATION UNDERLYING ADVERSE EVENTS

Brief overview of the leading COVID-19 vaccines

According to the COVID-19 vaccine tracker (<https://www.covid-19vaccinetracker.org>), currently 268 vaccines are in development, 97 are now in clinical testing, and 20 are in use as of 1 September 2021. The used platforms in COVID-19 vaccines include classical and novel platforms, such as viral vector (replicating and non-replicating), protein-based (protein subunit, virus-like particle), nucleic acid (RNA, DNA) and whole virus (inactivated or weakened) [25]. The two most common vaccines currently in use include mRNA-based (the Pfizer-BioNTech and Moderna) and adenovirus vector (the Johnson & Johnson and Oxford-AstraZeneca) vaccines.

Once mRNA vaccine is injected, the mRNA enters muscle cells, and the ribosomes perform cellular translation producing the spike protein, a viral receptor-binding domain that recognizes and binds to the host receptor angiotensin-converting enzyme 2. Subsequently, a robust CD8+ and CD4+T-cell-mediated response is triggered and eventually induces the production of neutralizing antibodies and memory T and B cells [26]. As for adenoviral vector vaccines, SARS-CoV-2 antigens were delivered by viral vector to invade the cell. The virus vector is physically or chemically weakened and therefore does not cause disease [27]. Within the host cell, the SARS-CoV-2 spike

protein antigen is expressed and triggers T-cell-mediated immune response [28, 29]. There are two leading viral vector vaccines currently in use including Janssen adenovirus-based vaccine and AstraZeneca adenovirus-based vaccine (ChAdOx1 nCoV-19). There are currently 17 non-replicating and two replicating viral vector candidate SARS-CoV-2 vaccines in clinical development [30]. The former has been approved by regulatory authorities around the world for emergency use [31].

However, dozens of different SARS-CoV-2 variants are spreading globally, including the Indian or Delta variant (B.1.617.2), and the United Kingdom or Alpha variant (B.1.1.7). The spread of SARS-CoV-2 variants is associated with antibody escape from the virus spike epitopes, possibly leading to reinfection and attenuating the effectiveness of all types of the vaccines [32, 33].

The potential mechanisms of immune activation triggered by COVID-19 vaccine

New-onset autoimmune manifestations following COVID-19 vaccination are being reported extensively [34–36]. The main mechanisms through which COVID-19 vaccine triggers autoimmunity include molecular mimicry, the production of particular autoantibodies and the role of certain vaccine adjuvants.

Previous studies have revealed that SARS-CoV-2 infection could trigger autoimmunity [37], but the association between COVID-19 vaccine and autoimmune phenomena remains nebulous. The respiratory system presented as the first organ invaded by SARS-CoV-2, which may be

TABLE 1 Search strategy of eligible literature

Database	Search terms	Search strategy
PubMed	#1 "COVID-19 Vaccines"[Mesh] OR "SARS-CoV-2 vaccine"	
	#2 "Autoimmune Diseases"[Mesh] OR "Autoimmunity" OR "Hepatitis, Autoimmune"[Mesh] OR "Purpura, Thrombocytopenic, Idiopathic"[Mesh] OR "Guillain-Barre Syndrome"[Mesh] OR "Lupus Erythematosus, Systemic"[Mesh] OR "Glomerulonephritis, IGA"[Mesh] OR "vaccine induced thrombotic thrombocytopenia"	#1 AND #2
Embase	#1 'covid-19 vaccine':ab,ti OR 'sars-cov-2 vaccine'/exp	
	#2 'autoimmune disease'/exp OR 'autoimmunity':ab,ti OR 'autoimmune hepatitis':ab,ti OR 'thrombocytopenic idiopathic purpura':ab,ti OR 'guillain-barre syndrome':ab,ti OR 'systemic lupus erythematosus':ab,ti OR 'IgA glomerulonephritis,':ab,ti OR 'vaccine induced thrombotic thrombocytopenia':ab,ti	#1 AND #2
Scopus	#1 TITLE-ABS-KEY ("covid-19 vaccine") OR TITLE-ABS-KEY ("SARS-CoV-2 vaccine")	
	#2 TITLE-ABS-KEY ("autoimmune diseases") OR TITLE-ABS-KEY ("autoimmunity") OR TITLE-ABS-KEY ("autoimmune hepatitis") OR TITLE-ABS-KEY ("thrombocytopenia idiopathic purpura") OR TITLE-ABS-KEY ("Guillain-Barre Syndrome") OR TITLE-ABS-KEY ("systemic lupus erythematosus") OR TITLE-ABS-KEY ("IgA glomerulonephritis") OR TITLE-ABS-KEY ("vaccine induced thrombotic thrombocytopenia")	#1 AND #2

involved in the cross-reactions between the immune response after SARS-CoV-2 infection and pulmonary surfactant proteins, because the SARS-CoV-2 spike glycoprotein and lung surfactant proteins shared 13 of 24 pentapeptides [38]. In addition, the cross-reaction between SARS-CoV-2 proteins and a variety of tissue antigens could lead to autoimmunity against connective tissue and the cardiovascular, gastrointestinal and nervous systems [39]. Infections act as environmental triggers to cause autoimmune diseases triggered by vaccines, while microbial antigens can elicit cross-reactive immune responses against self-antigens [19]. The immune cross-reactivity triggered by the similarity between certain vaccine components and specific human proteins could render immune system against pathogenic antigens to attack similar proteins in susceptible population and lead to autoimmune diseases, a process known as molecular mimicry. Influenza, hepatitis B and human papillomavirus vaccines have been suspected to trigger autoimmunity through molecular mimicry [18, 39]. In addition, only a minority of vaccinated subjects subsequently developed autoimmune phenomena, indicating a genetic predisposition to vaccine-induced autoimmunity.

Vaccine could trigger the adaptive immune response to display its protective effect, which may stimulate a hyperinflammatory condition. Post-vaccination healthy individuals exhibit acute increases in type I IFN expression, oxidative stress and DNA damage accumulation in blood mononuclear cells, coupled with effective anti-SARS-CoV-2-neutralizing antibody production [40]. Sprent and King deem that the side-effects of COVID-19 vaccines are simply a by-product of a transient burst of IFN-I generation concomitant with induction of an effective immune response [41]. However, the production of particular autoantibodies may be responsible for these adverse events. VITT events have been widely reported, which plausibly attributed to platelet factor 4 (PF4) antibody-mediated platelet activation through IgG-FcγR interactions [42]. Also, complement activation triggered by anti-PF4 antibodies appears to be implicated in VITT [43]. However, Greinacher A et al. found that PF4 antibodies induced by vaccination do not cross-react with the SARS-CoV-2 spike protein [44]. In addition, contact system activation by nucleic acid, complement recognition of the vaccine-activating allergic effector cells, pre-existing antibody recognition of polyethylene glycols (PEGs) and direct mast cell activation, coupled with potential genetic or environmental predispositions to hypersensitivity, account for anaphylaxis to COVID-19 mRNA vaccines [45].

Vaccine adjuvants could render vaccine immunogenicity by triggering the NLR pyrin domain containing 3 (NLRP3) inflammasome [46]. The mRNA contained in

mRNA vaccine present as both antigen and adjuvant, and is identified by endosomal Toll-like receptors (TLRs) and cytosolic inflammasome components, triggering inflammation and immunity [47]. The NLRP3 inflammasome displays a vital role in innate and adaptive immune system, as well as its contribution to several autoimmune diseases including rheumatoid arthritis, systemic lupus erythematosus (SLE), Sjögren's syndrome, systemic sclerosis and ankylosing spondylitis [48]. Vaccines based on mRNA-containing lipid nanoparticles (LNPs) are a promising new platform used by two leading vaccines against COVID-19. The LNP, with the potent adjuvant activity, was chosen as a carrier vehicle to protect the mRNA from degradation and aid intracellular delivery and endosomal escape. The LNPs are composed of a mixture of phospholipids, cholesterol, PEGylated lipids, and cationic or ionizable lipids. IgE-mediated reactions related to PEGs, an identified culprit, may be involved in anaphylactic reactions following COVID-19 vaccination [49, 50]. Other excipients than PEG, such as a buffer/oxidation inhibitor (histidine) and non-ionic surfactant (polysorbate 80) contained in the adenovirus-based AstraZeneca vaccine, could also display a potential role in anaphylaxis or serious hypersensitivity reactions after vaccination [51]. In mouse models, LNPs could trigger inflammatory responses, characterized by massive neutrophil infiltration, activation of diverse inflammatory pathways, and production of various inflammatory cytokines and chemokines, including the secretion of IL-1β/IL-6 and macrophage inflammatory protein-α and macrophage inflammatory protein-β [52] (Figure 1).

AUTOIMMUNE MANIFESTATIONS FOLLOWING COVID-19 VACCINE

Vaccine-induced thrombotic thrombocytopenia

Vaccine-induced thrombotic thrombocytopenia (VITT), also known as thrombosis with thrombocytopenia syndrome, clinically resembles the hallmarks of autoimmune heparin-induced thrombocytopenia (HIT) without any prior history of heparin exposure or known risk factors for thrombophilia. The affected patients are all young and previously healthy, and they have widespread thrombi, predominantly in atypical sites, encompassing cerebral venous sinus thrombosis (CVST), splanchnic vein thrombosis (SVT) and pulmonary emboli in combination with thrombocytopenia after receiving the COVID-19 vaccine. Emerging evidence has reported adverse events after COVID-19 vaccine as vaccination programmes are being rolled out globally.

Initial complications of thrombocytopenia and thrombosis associated with vaccination in atypical locations were mainly seen in the adenoviral-based COVID-19 vaccine. A case of a 62-year-old woman developed VITT and had aching joints, moderate headache, petechiae and haematomas after receiving ChAdOx1 nCoV-19 vaccine. The laboratory test showed thrombocytopenia, low fibrinogen, elevated D-dimer and positive platelet factor 4. She responded well to treatment with high-dose intravenous immunoglobulin (IVIg) and prednisolone [53]. A 27-year-old fit and well man had intermittent headaches, eye floaters and vomiting 2 days after vaccination, coupled with elevated D-dimer, low platelets and fibrinogen, positive PF4 antibodies and significant CVST [54]. An observational study of 492 healthcare workers from Norway reported a low prevalence of both thrombocytopenia and antibodies to PF4/polyanion complexes after vaccination with AZD1222 [55]. See et al. reported 12 patients of cerebral

venous sinus thrombosis with thrombocytopenia, and these patients were all women, younger than 60 years, and presented with symptom onset ranging from 6 to 15 days after vaccination requiring hospitalization [56]. Recently, Scully et al. described in detail the clinical and laboratory profiles of 22 patients in which acute thrombocytopenia and thrombosis were developed. Among these 22 patients, 14 cases were women, with an age range of 21–77 years (median age of 46 years), and 21 had elevated D-dimer levels, positive PF4 antibodies and abnormal fibrinogen levels. In addition, 13 of these 22 patients had CVST; four cases had pulmonary embolism, one case had deep vein thrombosis and bilateral adrenal haemorrhage, two cases had ischaemic stroke affecting the middle cerebral artery region, and two cases had portal vein thrombosis [57]. Schultz and colleagues reported that 5 patients aged 32–54 years had CVST and thrombocytopenia 7 to 10 days after vaccination. All patients had high levels of PF4-polyanion

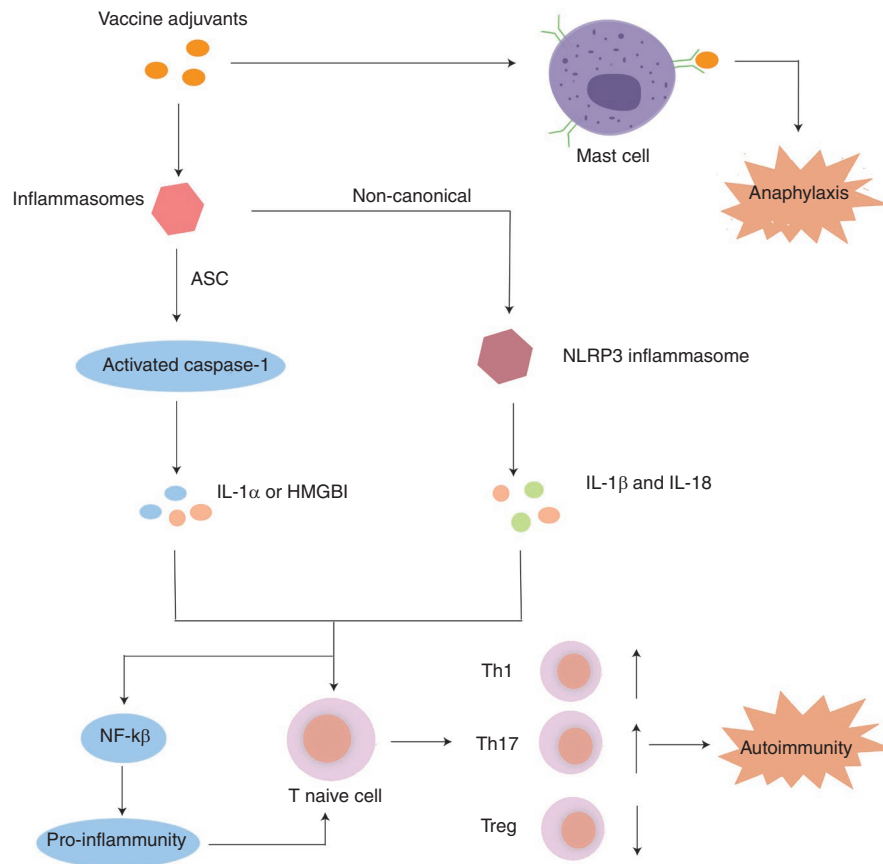


FIGURE 1 Potential mechanisms inducing autoimmunity through vaccine adjuvants. Vaccine adjuvants can activate inflammasomes. Canonical inflammasomes recruit caspase-1 via the adaptor molecule ASC, leading to activation of caspase-1 and the release of pro-inflammatory DAMPs such as IL-1 α or HMGB1. Non-canonical inflammasomes activate the NLRP3 inflammasome, which indirectly induces the maturation and secretion of IL-1 β and IL-18 via the non-canonical route, which bind to the receptors and activate the NF- κ B signalling pathway, ultimately leading to the upregulation of NLRP3, pro-IL-1 β and pro-IL-18. In addition, pre-existing antibody recognition of polyethylene glycols (PEGs) and direct mast cell activation, coupled with potential genetic or environmental predispositions to hypersensitivity, account for anaphylaxis to COVID-19 mRNA vaccines. ASC, apoptosis-associated speck-like protein containing a CARD; HMGB1, high-mobility group box 1; IL-1 α , interleukin-1 α ; IL-1 β , interleukin-1 β ; IL-18, interleukin-18; NF- κ B, nuclear factor kappa B; PEG, polyethylene glycol

antibodies, without previous exposure to heparin [58]. Greinacher et al. reported that 11 cases of Austrian and German origin had thrombosis or thrombocytopenia after COVID-19 vaccine. Nine of 11 patients were women, with a median age of 36 years (range 22–49 years). Among these 11 patients, nine cases had CVST, three cases had SVT, three cases had pulmonary embolism, and four cases had other blood clots [59]. A 50-year-old woman without personal or family history of venous thromboembolism and contraceptive use developed severe back pain and headache 10 days after vaccination. Laboratory investigations showed a severe thrombocytopenia, elevated serum D-dimer concentration and iron deficiency anaemia [60]. The first case was a 44-year-old male healthcare worker from Australia. He had received the first dose of the COVID-19 vaccine 8 days prior to presentation with fevers, fatigue, abdominal discomfort and increased bowel frequency. The laboratory results showed low platelet count, markedly elevated D-dimer, positive PF4 antibodies and thrombosis with complete occlusion of the portal and splenic veins [61]. There were two cases of CVST and thrombocytopenia after receiving vaccine. The first case had headache, left-sided incoordination and hemiparesis. The other patient was a 25-year-old man with previous primary sclerosing cholangitis (PSC) and migraines, who developed more severe headache, photophobia, neck stiffness and visual disturbances, and the PF4 antibody was positive. Both cases had neurological deterioration and died [62]. On the contrary, based on a national prospective cohort, Simpson et al. found that no positive associations were seen linking COVID-19 vaccination to thrombocytopenic, haemorrhagic and thromboembolic events [63]. A cohort including 148 792 people in Denmark and 132 472 in Norway, who accepted the first dose of ChAdOx1 nCoV-19, found higher rates of venous thromboembolic events than general population [64]. A 41-year-old man accepted his first dose of ChAdOx1 nCoV-19 vaccination 11 days prior to presentation with headache, severe thrombocytopenia, increased D-dimer and extensive thrombosis of the whole portal venous system [65]. A 50-year-old white man in good health suffered from a worsening headache. The CT scan of his brain revealed intraparenchymal haemorrhage in the left cerebral hemisphere, and CT angiography revealed multiple small bleeding sites [66]. A 55-year-old woman had conjunctival congestion, retro-orbital pain and diplopia, coupled with marked thrombocytopenia and positive IgG antiplatelet antibodies. She was diagnosed with bilateral SOVT, immune thrombocytopenic purpura (ITP) and ischaemic stroke [67]. A 51-year-old woman developed dyspnoea, fatigue and cough, coupled with a severe thrombocytopenia, elevated D-dimer and C-reactive protein, central pulmonary embolism and venous thrombus [68]. A case of a 40-year-old woman with migraines

and obesity had a sudden headache, body aches, fever and chills. Laboratory results demonstrated thrombocytopenia, elevated D-dimer, positive PF4 antibodies, pulmonary emboli and dural venous sinus thrombosis [69]. In addition, Muir et al. reported a case of a 48-year-old White woman who developed mild anaemia, severe thrombocytopenia, low fibrinogen level and elevated D-dimer, suggesting a diffuse intravascular coagulation-like state. Additional tests revealed CVST and extensive SVT [70]. However, the distinction in VITT events following two adenoviral vector vaccines (i.e. Ad26.COV.2.S and ChAdOx1 nCoV-19) has not been elucidated. Hwang et al. concluded that CVT after vaccination with Ad26.COV.2 occurred later than vaccination with ChAdOx1 nCoV-19, with similar mortality despite more thrombosis and cerebral haemorrhage, and lower D-dimer and activated partial thromboplastin time level [71].

In addition to adenovirus vector vaccine, thrombotic events related to other vaccine occurred as the expansion of vaccination coverage. Welsh et al. reported 15 and 13 cases of thrombocytopenia among 16 260 102 doses of COVID-19 vaccine (Moderna) and 18 841 309 doses of COVID-19 vaccine (Pfizer-BioNTech), respectively [72]. A 39-year-old female patient received a second dose of the BNT162b2 COVID-19 vaccine 3 days prior to the onset of fatigue, muscle aches and petechial rash on her trunk, legs and arms, and profound thrombocytopenia [73]. Fueyo-Rodriguez et al. reported a 41-year-old woman had received the BNT162b2 COVID-19 vaccine 12 h prior to presentation with fever, tachycardia and nausea. Blood tests showed remarkably moderate thrombocytopenia, elevated C-reactive protein and IgE [74].

There are several putative mechanisms by which COVID-19 vaccine triggers immune thrombotic thrombocytopenia (ITT). First, Greinacher and colleagues considered that COVID-19 vaccination causes a rare ITT mediated by activation of antibodies against PF4 that stimulate platelets through their Fc γ receptors. This rare adverse reaction closely mimics the clinical presentation of classical immune-mediated HIT disease that occurs after exposure to heparin. Surprisingly, none of these patients had been exposed to heparin prior to the onset [59]. In addition, this process appears to be involved in molecular mimicry, a well-established mechanism that may lead to autoimmunity associated with multiple viruses, inducing antibody-mediated responses to homologous components of viruses, which may cross-react with self-antigens and result in autoimmune diseases [75–78]. However, Greinacher A et al. found no cross-reactivity between vaccine-induced PF4 antibodies and SARS-CoV-2 spiked protein, suggesting that the vaccine-induced immune response to

SARS-CoV-2 spiked protein is not triggered by VITT [44]. In addition, the adenovirus–platelet–leucocyte complexes lead to platelet activation, mediated by p-selectin and von Willebrand factor, which may result in accelerated platelet clearance in the liver [79], suggesting that thrombocytopenia after adenovirus vaccination is frequent [80]. The prothrombotic disease VITT usually begins at least 1 week after vaccination. However, the virus is not replicable and circulating virus may disappear 1–2 weeks after vaccination, so viral localization to the central nervous system and intestine is unlikely to cause thrombosis at these sites [81]. Polysorbate 80, a commonly utilized non-ionic surfactant and drug stabilizer that is known to be effective in entering brain endothelial cells and crossing the blood–brain barrier when complexed with nanoparticles [82], could localize thrombosis to the central nervous system and trigger a pathogenic cascade [83]. However, Eichinger et al. argued that polysorbate 80 is unlikely to be present one or more weeks after vaccination when VITT occurs [81]. Antiphospholipid antibodies (APLs) may be partly responsible for thrombotic events after COVID-19 vaccination, and it may trigger a type I interferon response associated with the production of APLs. It appears to be associated with an abnormally activated immune response involving innate immune cells, cytokines and complement cascade reactions [84]. Also, complement activation triggered by anti-PF4 antibodies appears to be implicated in VITT [43] (Figure 2).

Given the bulk of evidence related to VITT post-COVID-19 vaccination, we have summarized the following clinical features. First, the majority of patients are healthy and with the absence of personal or family history of thromboembolic events. Second, the mean time to onset of symptoms after vaccination is 8 days. It may affect patients of all ages and both sexes, especially younger female individuals, age of these patients predominantly range from 27 to 62 years. Third, most patients without prior heparin exposure presented with elevated serum D-dimer, low fibrinogen level and positive PF4 antibodies in laboratory tests, accompanied by widespread thrombi, predominantly in atypical sites, encompassing CVST, SVT and pulmonary emboli in combination with thrombocytopenia. The primary treatment option is no-heparin anticoagulants and IVIg for patients with VITT [85].

Immune thrombocytopenic purpura

ITP is an autoimmune condition, characterized by decreased platelet level, which leads to mucocutaneous and other bleedings. Recently, there is growing evidence that

new-onset ITP occurred after COVID-19 vaccination. The first case of ITP was a woman of 28 years old, who presented with fever, fatigue and headache, coupled with purpura on the trunk, extremities and bleeding lesions in the oral cavity following the AZD1222 administration [86]. The second patient was a 72-year-old woman who received the Moderna COVID-19 vaccine 1 day prior to presentation with reduced platelet, a rash, spontaneous oral bleeding, headache and diffuse petechiae across her arms, legs, and abdomen and haemorrhagic bullae of the gingival mucosa [87]. A 26-year-old woman who had a petechial rash associated with thrombocytopenia 2 weeks after vaccination. Her liver function tests showed ITP and acute liver injury [88]. A 67-year-old patient from Hispanic had petechial rashes on her legs and chest 2 weeks after receiving the first dose of COVID-19 vaccine (Pfizer-BioNTech). Then, she received the second dose of the vaccine two days prior to developed bleeding in her gums, a rapid rash covering her body and a subconjunctival haemorrhage in the right eye [89]. Two cases of acute ITP developed severe thrombocytopenia of unknown causes after administration of ChAdOx1 [90]. Perricone et al. previously had summarized a set of ITP cases related to vaccination. This may be involved in the molecular mimicry that pathogenic antibodies bind platelet and megakaryocytes leading to thrombocytopenia through opsonization, complement activation and apoptotic pathways [91].

Autoimmune liver diseases

Autoimmune liver diseases represent a group of chronic inflammatory hepatobiliary diseases, including three distinct clinical manifestations, that is autoimmune hepatitis (AIH), primary biliary cholangitis (PBC) and PSC [92, 93]. Environmental triggers (e.g. viruses, drugs and herbal products) could induce loss of self-tolerance to liver autoantigens. Previous studies have suggested that influenza and hepatitis A vaccines can cause AIH [94, 95]. However, emerging evidence has revealed a few cases regarding the onset of autoimmune liver diseases following COVID-19 vaccine.

The first case was a 35-year-old Caucasian woman in her third month postpartum. She developed generalized pruritus, choloria and jaundice 13 days after receiving COVID-19 vaccine, coupled with positive antinuclear antibody and double-stranded DNA antibodies [96]. However, Capecchi PL et al questioned that the recent pregnancy represents a tremendous confounding factor associated with the development of AIH, rather than the COVID-19 vaccine [97]. However, two additional male cases excluded pregnancy as a confounding factor. The first case was a 36-year-old male physician from Iraqi, who had

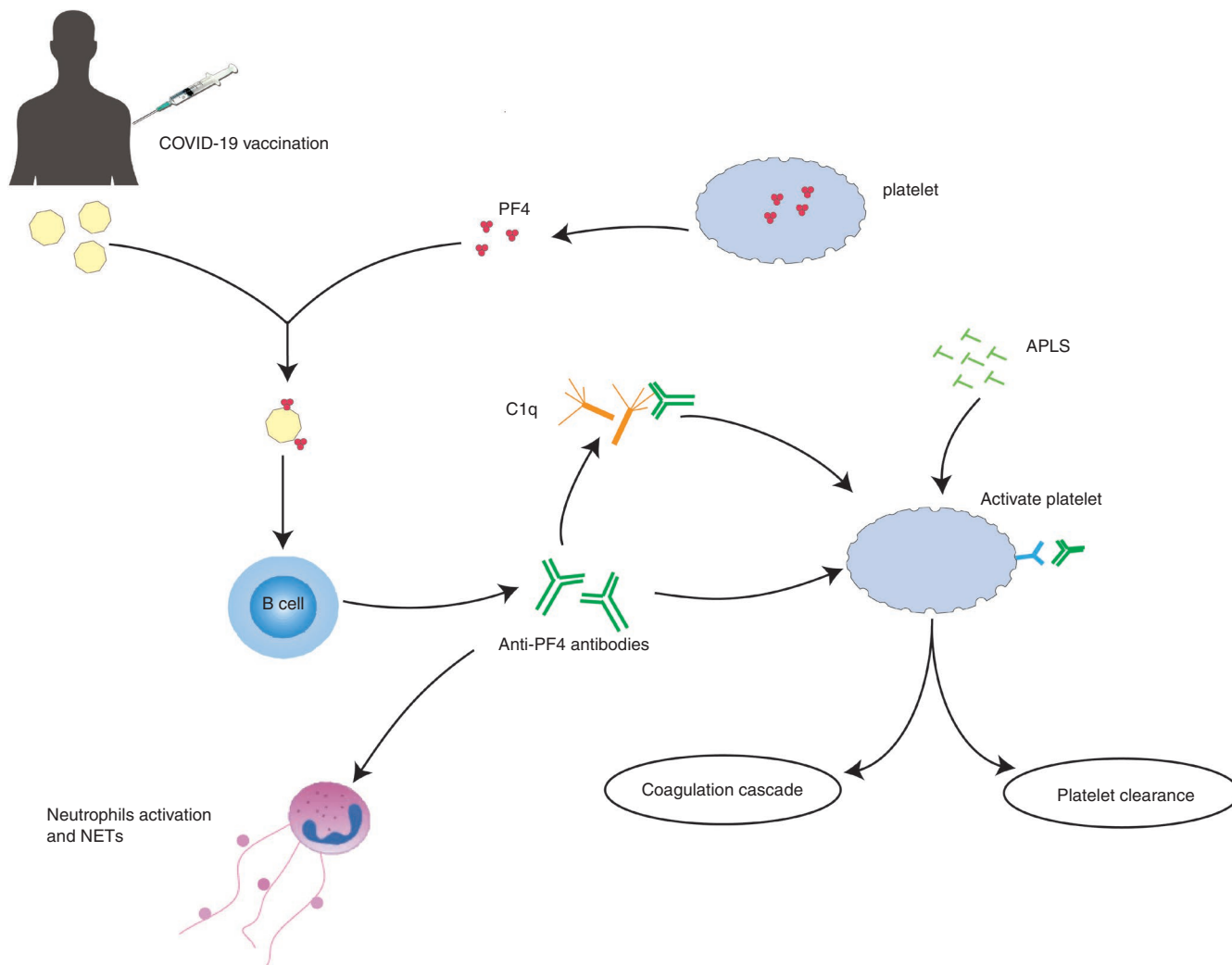


FIGURE 2 Schematic depiction of mechanisms inducing vaccine-induced immune thrombotic thrombocytopenia following COVID-19 vaccination. APLs may represent a risk factor for thrombotic events following COVID-19 vaccination. APLs trigger a type I interferon response. It may inhibit anticoagulant pathway of protein C and directly bind platelets, triggering the coagulation cascade. It appears to be implicated in the aberrant activation of the immune response with participation of innate immune cells, cytokines and the complement cascade. In addition, COVID-19 vaccination can contribute to the rare development of immune thrombotic thrombocytopenia mediated by activating antibodies against PF4 that stimulate platelets through their Fcγ receptors. This rare adverse effect extremely resembles the clinical presentation of the classical immune-mediated HIT disorder. Complement activation triggered by anti-PF4 antibodies appears to be implicated in VITT. PF4-containing immune complexes can be recognized by C1q, which binds to the Fc portion of IgG molecule, thereby leading to C3 activation, amplification of complement responses and downstream generation of potent pro-inflammatory mediators and effectors, culminating in the enhancement of thromboinflammation. APLs, antiphospholipid antibodies; PF4, platelet factor 4; IgG, immunoglobulin G; VITT, vaccine-induced immune thrombotic thrombocytopenia; HIT, heparin-induced thrombocytopenia; COVID-19, coronavirus disease 2019

mild febrile reaction and markedly abnormal liver function tests 26 days after vaccination with ChAdOx1 nCoV-19. Liver biopsy showed interfacial hepatitis with a mixed inflammatory cell infiltrate dominated by lymphocytes, without significant fibrosis. The post-biopsy pretreatment Revised Original Score for Autoimmune Hepatitis is 15 [98]. Another case was a man of 63 years old who received his first dose of SARS-CoV-2 vaccine 7 days prior to presentation with acute severe autoimmune-like hepatitis and was well treated with prednisone, without

a history of SARS-CoV-2 natural infection or autoimmunity. Intriguingly, the patient carried the protective gene against PBC and without susceptibility genes of HLA alleles DRB1*03 and DRB1*04 [99]. An 80-year-old woman without alcohol use or smoking presented with high liver enzyme levels, jaundice, hyperchromic urine and interface hepatitis 1 week after receiving BNT162b2 mRNA vaccination and responded well to treatment by prednisone. The laboratory findings showed that aspartate aminotransferase (AST), alanine aminotransferase (ALT), bilirubin,

alkaline phosphatase (ALP), gamma-glutamyltransferase, antinuclear antibody (ANA) and total IgG were positive [100]. Similar to the previously described cases, a 71-year-old Caucasian woman developed jaundice and positive bilirubin, ALP and ALT 4 days after receiving COVID-19 mRNA vaccination (McShane et al. [101]). In addition, a 41-year-old woman developed epigastric pain, nausea, and vomiting with choluria and jaundice after receiving mRNA-1273 vaccine, eventually diagnosed with vaccine-induced AIH. Laboratory results were positive for ANA, anti-smooth muscle antibody, anti-soluble liver antigen and anti-liver cytosol, and corticosteroid treatment with high-dose prednisone (1 mg/kg) was started with rapid normalization of liver enzymes [102]. A 76-year-old woman had received COVID-19 vaccination prior to the presentation of autoimmune hepatitis with positive anti-smooth muscle antibody and elevated immunoglobulins G, and typical histological findings [103]. Rela et al. reported two patients of AIH caused by COVID vaccination (Covishield). One case was a 38-year-old woman health-care worker who developed deep jaundice, pedal oedema and dark urine, coupled with markedly elevated total bilirubin, AST and ALT on liver function tests. Another case was a 62-year-old diabetic man who had fever, anorexia and jaundice after vaccination. The liver function tests of ALT, AST and total bilirubin were elevated as well. His liver biopsy showed porto-central bridging necrosis and mild portal fibrosis, and eventually, he succumbed to the liver disease [104].

Based on current case reports, the type of vaccine that causes autoimmune hepatitis is primarily mRNA vaccine produced by Pfizer-BioNTech and Moderna. The mean time to onset of symptoms after vaccination is 13 days, ranging from 4 to 26 days. The main clinical manifestations include jaundice, interface hepatitis and abnormal liver function tests. Although the causal link between the SARS-CoV-2 vaccine and AIH cannot be definitively established, these case reports suggest that this association could be more than coincidental. The reasonable lag time linking vaccination to the typical onset of symptoms and the laboratory results, as well as good response to treatment, further validate the association between AIH and SARS-CoV-2 vaccination. However, pregnancy or drug use may serve as confounding factors that exaggerate this association. More evidence is warranted to further elucidate the exact causality.

Guillain-Barré syndrome

Guillain-Barré syndrome (GBS) is a rare autoimmune neurological disorder that affects the peripheral nerves and nerve roots, induced by certain infections such as

cytomegalovirus, Epstein-Barr virus and Zika virus [105]. Previous studies have shown that GBS was associated with vaccines for rabies, hepatitis A and B, and influenza. Emerging evidence indicated that GBS could occur following COVID-19 vaccination.

The first case, an 82-year-old woman, had general discomfort and body pain during the first week after receiving her vaccination. Cerebrospinal fluid analysis showed separation of albumin cells and strengthening of the cauda equina nerve roots, compatible with the diagnosis of GBS [106]. In the context of COVID-19 vaccination, bifacial weakness may be an initial symptom of GBS [107]. A 62-year-old woman had gradual weakness of bilateral lower limbs preceded by paraesthesia and numbness 11 days after receiving her first dose of COVID-19 vaccine, coupled with marked demyelinating sensorimotor polyneuropathy [108]. A 73-year-old gentleman developed progressive bilateral lower limb weakness 20 days after receiving the second dose of COVID-19 vaccine. Bilateral H reflexes deficit in gastrocnemius and elevated protein and albumin, consistent with early polymerogenic neuropathy [109]. Patel et al. reported a case who had a rapidly progressive ascending muscle weakness and back pain 3 weeks after receiving his first dose of COVID-19 ChAdOx1 vaccine, eventually diagnosed with GBS and well responded to IVIg [110]. A case of 48-year-old man developed left-sided lower motor neuron facial weakness and severe back pain following vaccination, with multifocal sensorimotor demyelinating polyneuropathy. The House Brackmann grade developed from III to V paralysis bilaterally and his symptoms were improved for treatment with IVIg and oral prednisolone [111]. Allen et al. reported 4 cases of the bifacial weakness with paraesthesia variant of GBS that developed after receiving SARS-CoV-2 vaccine. The symptoms occur 11–22 days after vaccination, which is the point when the vaccine produces the maximum immune response [112]. Five remarkably similar cases developed bifacial weakness with paranesthesia of limbs 7–12 days after vaccination with Vaxzevria [113]. In addition, seven of 1.5 million people in three districts of Kerala, India, had severe GBS within 2 weeks of the first dose of vaccine, an incidence 1.4–10 times higher than expected for the population [114]. According to Vaccine Adverse Event Reporting System, 130 cases of presumptive GBS were confirmed following vaccination with Ad26.COV2.S as of 24 July 2021, and the observed-to-expected rate increased in all age groups apart from individuals aged 18–29 years [115]. However, among a cohort of 3,890,250 recipients from Hispanic vaccination with BNT162b2 mRNA vaccine, seven cases of GBS were found within 30 days after first-dose vaccine administration and no cases occurred after second-dose administration for an observed incidence of 0.18/100 000 administered doses, suggesting that

the association between GBS and BNT162b2 vaccine remained far-fetched [116]. Similarly, Lunn et al. proposed that when considering a more optimistic 4-billion-person immunization programme conducted over 1 year, 68 000 cases of GBS would be expected to occur naturally during this period regardless of any immunization plan; this cannot be considered causal [117].

Given the aforementioned evidence, the majority of GBS cases shared certain similar clinical features. First, an interval of 1–3 weeks between vaccination and the onset of symptoms supports a temporary causal relationship. Second, bifacial weakness with paresthesia of limbs, back pain, and demyelinating polyneuropathy are common symptoms of GBS onset after vaccination. Lastly, most patients have a good prognosis and respond well to IVIg.

IgA nephropathy

IgA nephropathy is the most common form of primary glomerulonephritis worldwide and results in renal failure in 20%–40% of patients within 20 years of diagnosis. Recently, several case reports suggest that COVID-19 vaccination may be a trigger for IgA nephropathy. For instance, a 30-year-old man, without family history of kidney disease, developed fevers, headache and brown-coloured urine, coupled with new-onset haematuria and proteinuria 1 day after vaccination, eventually diagnosed with IgA nephropathy [118]. Two healthy individuals had received COVID-19 vaccination shortly prior to presentation with macroscopic haematuria, diagnosed with IgA nephropathy and crescentic glomerulonephritis, respectively. The first case had headache, generalized myalgia and new-onset macroscopic haematuria, coupled with proteinuria and elevated serum creatinine. Renal biopsy showed IgA nephropathy with fibrocellular and fibrous crescents. The other patient was a 60-year-old female presented with macroscopic haematuria, proteinuria and acute kidney injury. Both patients did not have history of IgA nephropathy and COVID-19 infection [119]. In addition, patients with IgA nephropathy suffered from macroscopic haematuria <24 h and gross haematuria after Pfizer COVID-19 vaccination, suggesting that COVID-19 vaccines may also aggravate the recurrence of existing autoimmune diseases [120, 121]. A causal link between mRNA vaccines and IgA nephropathy has not been previously evaluated. The causal relationship between the COVID-19 vaccine and IgA nephropathy still cannot be concluded prematurely. Only multicentre and longitudinal studies enrolling cases globally can truly validate the associations.

Inflammatory arthritis

Arthralgia is reported in 30.3% of people following the Sputnik V COVID-19 vaccination in Iran [122]. A cross-sectional study of 724 patients with rheumatic and musculoskeletal diseases showed that four of them reported episodes of arthritis following ChAdOx1 or BBV152 vaccination [123]. The first was the confirmed case of arthritis in a patient without a history of chronic joint disease and SARS-CoV-2 infection, who presented with a moderate effusion and a small joint synovitis in the left elbow fossa and shoulder–elbow after receiving Sputnik V vaccine [124]. The second was a 23-year-old woman who developed swollen and painful left knee joint after CoronaVac vaccination, diagnosed with reactive arthritis and responded well to treatment with compound betamethasone [125]. The third was a 38-year-old Asian woman without other potential triggers, presented with pain, stiffness and swelling in both knee joints and shoulders following the first dose of the Sputnik V vaccine, and accompanied by positive rheumatoid factor, anti-citrullinated protein antibodies and C-reactive protein. She was diagnosed with early rheumatoid arthritis and treated with methotrexate, non-steroidal anti-inflammatory drugs and methylprednisolone [126]. The fourth was a 49-year-old male who developed bilateral hand pain, swelling and stiffness 3 days following the first dose of the vaccine, diagnosed with autoimmune polyarthritis triggered by the vaccine and responded well to treatment by prednisone, with slightly elevated C-reactive protein and anti-citrullinated protein antibody [127]. Similarly, the US Food and Drug Administration (FDA) also perceived that COVID-19 vaccination (mRNA-1273) is plausibly related to the onset of rheumatoid arthritis [128].

Other autoimmune manifestations

In addition to the complications described above, other autoimmune manifestations have been reported in some cases, such as SLE, lupus nephritis and Graves' disease. A 22-year-old woman had pain in right knee and fever for 15 days following COVID-19 vaccination, and subsequently developed polyarthralgia, bipedal oedema, cutaneous rash on fingertips and petechiae on lower limb after 10 days, coupled with positive antinuclear antibody and raised immunoglobulin values. She was diagnosed with SLE and anaemia of chronic diseases and was well responded to treatment with prednisone and hydroxychloroquine [129]. A 23-year-old woman presented with abrupt eyelid oedema, foamy urine and nephrotic syndrome 1 week after vaccination with the first dose of the

TABLE 2 Different new-onset autoimmune phenomena following diverse COVID-19 vaccines

Autoimmune phenomena	Vaccine type
Vaccine-induced immune thrombotic thrombocytopenia	Adenovirus vector vaccine and mRNA vaccine
Immune thrombocytopenic purpura	mRNA vaccine
Autoimmune liver diseases	mRNA vaccine and Adenovirus vector vaccine
Guillain–Barré syndrome	mRNA vaccine and Adenovirus vector vaccine
IgA nephropathy	mRNA vaccine
Autoimmune polyarthritis	mRNA vaccine
Rheumatoid arthritis	mRNA vaccine and Adenovirus vector vaccine
Graves' disease	mRNA vaccine
Type 1 diabetes mellitus	mRNA vaccine
Systemic lupus erythematosus	Adenovirus vector vaccine

AZD1222 (ChAdOx1-S) vaccine, and eventually diagnosed with SLE with class V lupus nephritis [130]. A case with subacute cutaneous lupus erythematosus converted to SLE after AZD1222 inoculation [131]. Several reports also revealed that Graves' disease can occur after SARS-CoV-2 vaccination, which plausibly involved in a pathogenic immune response triggered by vaccine adjuvants [132, 133]. In addition, a case with a history of vitiligo vulgaris and type 2 diabetes, suffered from fever, weight loss, asthenia and thyrotoxicosis 4 weeks after the administration of SARS-CoV-2 vaccine, diagnosed as Graves' disease and type 1 diabetes mellitus [134]. As vaccination programmes are being rolled out globally, the emerging autoimmune phenomena are surfacing gradually. The post-vaccination surveillance programme and ongoing follow-up are warranted to ensure data collection on these associations to assess causality.

PERSPECTIVE

In addition, to our knowledge, this is the first time to systematically review the new-onset autoimmune manifestations following COVID-19 vaccine. Although information about the risk of autoimmune disease as a consequence of vaccination is controversial, we merely propose our current understanding of autoimmune manifestations associated with COVID-19 vaccine. However, we still have a great deal of tough and unresolved issues. For instance, it is debatable whether to continue with subsequent vaccinations for patients who develop autoimmune manifestations after the first dose of vaccine. Moreover, there are no general criteria for the diagnosis of vaccine-induced autoimmune disease, which has to be evaluated on a case-by-case basis. The current issues are as follows: first, clinicians should apply four basic principles to evaluate causal associations between the administration of COVID-19 vaccines

and autoimmune phenomena, including the consistency, strength, specificity of the link and the temporal relation [19]; second, we should compare the degree of vaccine-related risk with the corresponding natural infection-associated risk for the whole population or a specific subgroup; and third, appropriate epidemiological studies and animal models are warranted to identify the exact causality and elucidate the underlying biological mechanisms. For these susceptible populations, the risk of vaccine-induced autoimmune diseases should be weighed against the risk of exposure to SARS-CoV-2 infection. The information discussed above helps to guide clinical assessment and management of autoimmune manifestations post-COVID-19 vaccination, which is pivotal in taking precautionary measures and managing vaccine hesitancy.

CONCLUSION

In the light of the information discussed above, emerging evidence has indicated that new onset of autoimmune manifestations including VITT, autoimmune liver diseases, GBS and IgA nephropathy appears to be associated with COVID-19 vaccines (Table 2). The plausible mechanisms by which COVID-19 vaccines lead to autoimmune manifestations include molecular mimicry, the production of particular autoantibodies and the role of certain vaccine adjuvants. Further studies are warranted to elucidate the underlying biological mechanisms and identify the exact causality.

In terms of treatment measures, standard therapies for vaccine-induced autoimmunity have not been defined currently. Based on the aforementioned evidence, once the diagnosis of certain particular autoimmune disease has been confirmed, symptomatic treatment should be administered, such as disease-modifying anti-rheumatic drugs (DMARDs), non-steroidal anti-inflammatory drugs

(NSAIDs) and glucocorticoids for rheumatic diseases, intravenous immunoglobulin for Guillain–Barré syndrome, and prednisone for autoimmune liver diseases and SLE. Of note, using no-heparin anticoagulants and intravenous immunoglobulin to treat patients with VITT is also recommended.

Although allergic reactions to vaccines are rare, as vaccination programmes are being rolled out globally, many vaccine-related side-effects are being reported. Importantly, we do not aim to disavow the overwhelming benefits of mass vaccination with COVID-19 in controlling COVID-19 pandemic and preventing COVID-19 morbidity and mortality. We encourage and support COVID-19 vaccination globally to create an immunity barrier among population. Systematic monitoring and ongoing follow-up of autoimmune events will be critical in identifying potential associations between autoimmune manifestations and COVID-19 vaccination, specific mechanisms of diagnosis and risk stratification for future vaccination. In addition, most of the included literature were case reports or cross-sectional studies, showing only a temporal association. Despite limitations of this review, these reports could help guide clinical assessment and management of autoimmune manifestations after COVID-19 vaccination.

CONFLICT OF INTEREST

The authors declare that they have no competing interests.

AUTHOR CONTRIBUTIONS

HFP and DQY conceptualized the review. PW performed the literature search. XML and ZWS performed supervision. YC and ZX prepared the first draft and edited the manuscript. All authors commented on previous versions of the manuscript and read and approved the final manuscript.

ORCID

Hai-Feng Pan  <https://orcid.org/0000-0001-8218-5747>

REFERENCES

- COVID-19 Dashboard 2021. Available from: <https://coronavirus.jhu.edu/map.html>. Accessed September 1, 2021.
- Guan W-J, Ni Z-Y, Hu YU, Liang W-H, Ou C-Q, He J-X, et al. Clinical characteristics of coronavirus disease 2019 in China. *N Engl J Med*. 2020;382:1708–20.
- Wu Z, McGoogan JM. Characteristics of and important lessons from the coronavirus disease 2019 (COVID-19) outbreak in China: summary of a report of 72314 cases from the chinese center for disease control and prevention. *JAMA*. 2020;323:1239–42.
- Zhang Q, Wang Z, Lv Y, Zhao J, Dang Q, Xu D, et al. Clinical features and prognostic factors of patients with COVID-19 in Henan Province, China. *Hum Cell*. 2021;34:419–35.
- Huang Q, Wu X, Zheng X, Luo S, Xu S, Weng J. Targeting inflammation and cytokine storm in COVID-19. *Pharmacol Res*. 2020;159:105051.
- Hojyo S, Uchida M, Tanaka K, Hasebe R, Tanaka Y, Murakami M, et al. How COVID-19 induces cytokine storm with high mortality. *Inflamm Regen*. 2020;40:37.
- Chen R, Lan Z, Ye J, Pang L, Liu YI, Wu W, et al. Cytokine storm: the primary determinant for the pathophysiological evolution of COVID-19 deterioration. *Front Immunol*. 2021;12:589095.
- Ahmed S, Zimba O, Gasparyan AY. Thrombosis in Coronavirus disease 2019 (COVID-19) through the prism of Virchow's triad. *Clin Rheumatol*. 2020;39:2529–43.
- Carbillon L, Fermat M, Benbara A, Boujenah J. COVID-19, Virchow's triad and thromboembolic risk in obese pregnant women. *Clin Cardiol*. 2021;44:593–4.
- Kipshidze N, Dangas G, White CJ, Kipshidze N, Siddiqui F, Lattimer CR, et al. Viral coagulopathy in patients with COVID-19: treatment and care. *Clin Appl Thromb/Hemost*. 2020;26:1076029620936776.
- Mathieu E, Ritchie H, Ortiz-Ospina E, Roser M, Hasell J, Appel C, et al. A global database of COVID-19 vaccinations. *Nat Hum Behav*. 2021;5:947–53.
- Dagan N, Barda N, Kepten E, Miron O, Perchik S, Katz MA, et al. BNT162b2 mRNA Covid-19 vaccine in a nationwide mass vaccination setting. *N Engl J Med*. 2021;384:1412–23.
- Hause AM, Gee J, Baggs J, Abara WE, Marquez P, Thompson D, et al. COVID-19 vaccine safety in adolescents aged 12–17 years - United States, December 14, 2020–July 16, 2021. *MMWR Morb Mortal Wkly Rep*. 2021;70:1053–8.
- Rosenblum HG, Hadler SC, Mouliat D, Shimabukuro TT, Su JR, Tepper NK, et al. Use of COVID-19 vaccines after reports of adverse events among adult recipients of Janssen (Johnson & Johnson) and mRNA COVID-19 vaccines (Pfizer-BioNTech and Moderna): update from the advisory committee on immunization practices - United States, July 2021. *MMWR Morb Mortal Wkly Rep*. 2021;70:1094–9.
- McMahon DE, Amerson E, Rosenbach M, Lipoff JB, Moustafa D, Tyagi A, et al. Cutaneous reactions reported after Moderna and Pfizer COVID-19 vaccination: a registry-based study of 414 cases. *J Am Acad Dermatol*. 2021;85:46–55.
- Esquivel-Valerio JA, Skinner-Taylor CM, Moreno-Arquieta IA, Cardenas-de la Garza JA, Garcia-Arellano G, Gonzalez-Garcia PL, et al. Adverse events of six COVID-19 vaccines in patients with autoimmune rheumatic diseases: a cross-sectional study. *Rheumatol Int*. 2021;41:2105–8.
- Pellegrino P, Carnovale C, Pozzi M, Antoniazzi S, Perrone V, Salvati D, et al. On the relationship between human papilloma virus vaccine and autoimmune diseases. *Autoimmun Rev*. 2014;13:736–41.
- Segal Y, Shoenfeld Y. Vaccine-induced autoimmunity: the role of molecular mimicry and immune crossreaction. *Cell Mol Immunol*. 2018;15:586–94.
- Wraith DC, Goldman M, Lambert P-H. Vaccination and autoimmune disease: what is the evidence? *The Lancet*. 2003;362:1659–66.
- Montgomery J, Ryan M, Engler R, Hoffman D, McClenathan B, Collins L, et al. Myocarditis following immunization with mRNA COVID-19 vaccines in members of the US Military. *JAMA Cardiol*. 2021;6:1202.

21. Arepally GM, Ortel TL. Vaccine-induced immune thrombotic thrombocytopenia: what we know and do not know. *Blood*. 2021;138:293–8.
22. Elrashdy F, Tambuwala MM, Hassan SS, Adadi P, Seyran M, Abd El-Aziz TM, et al. Autoimmunity roots of the thrombotic events after COVID-19 vaccination. *Autoimmun Rev*. 2021;20:102941.
23. Badier L, Toledano A, Porel T, Dumond S, Jouglan J, Sailler L, et al. IgA vasculitis in adult patient following vaccination by ChadOx1 nCoV-19. *Autoimmun Rev*. 2021;20:102951.
24. Bunders MJ, Altfeld M. Implications of sex differences in immunity for SARS-CoV-2 pathogenesis and design of therapeutic interventions. *Immunity*. 2020;53:487–95.
25. van Riel D, de Wit E. Next-generation vaccine platforms for COVID-19. *Nat Mater*. 2020;19:810–2.
26. Wack S, Patton T, Ferris LK. COVID-19 vaccine safety and efficacy in patients with Immune-Mediated Inflammatory Disease: Review of available evidence. *J Am Acad Dermatol*. 2021;85:1274–84.
27. Rauch S, Jasny E, Schmidt KE, Petsch B. New vaccine technologies to combat outbreak situations. *Front Immunol*. 2018;9:1963.
28. Chen Y, Li L. SARS-CoV-2: virus dynamics and host response. *Lancet Infect Dis*. 2020;20:515–6.
29. Ndwandwe D, Wiysonge CS. COVID-19 vaccines. *Curr Opin Immunol*. 2021;71:111–6.
30. WHO COVID-19 Vaccine Tracker and Landscape 2021. Available from: <https://www.WHO.int/publications/m/item/draft-lands-cape-of-covid-19-candidate-vaccines>. Accessed August 17, 2021.
31. WHO Status of COVID-19 Vaccines within WHO EUL/PQ Evaluation Process 2021. Available from: https://extra.net.WHO.int/pqweb/sites/default/files/documents/Status_COVID_VAX_29June2021. Accessed June 29, 2021.
32. Rehman SU, Rehman SU, Yoo HH. COVID-19 challenges and its therapeutics. *Biomed Pharmacother*. 2021;142:112015.
33. McCarthy KR, Rennick LJ, Nambulli S, Robinson-McCarthy LR, Bain WG, Haidar G, et al. Recurrent deletions in the SARS-CoV-2 spike glycoprotein drive antibody escape. *Science*. 2021;371:1139–42.
34. Cabanillas B, Novak N. Allergy to COVID-19 vaccines: a current update. *Allergol Int*. 2021;70:313–8.
35. Cabanillas B, Akdis CA, Novak N. COVID-19 vaccine anaphylaxis: IgE, complement or what else? A reply to: "COVID-19 vaccine anaphylaxis: PEG or not?". *Allergy*. 2021;76:1938–40.
36. Klimek L, Novak N, Cabanillas B, Jutel M, Bousquet J, Akdis CA. Allergenic components of the mRNA-1273 vaccine for COVID-19: Possible involvement of polyethylene glycol and IgG-mediated complement activation. *Allergy*. 2021;76:3307–13.
37. Ehrenfeld M, Tincani A, Andreoli L, Cattalini M, Greenbaum A, Kanduc D, et al. Covid-19 and autoimmunity. *Autoimmun Rev*. 2020;19:102597.
38. Kanduc D, Shoenfeld Y. On the molecular determinants of the SARS-CoV-2 attack. *Clin Immunol*. 2020;215.
39. Vojdani A, Kharrazian D. Potential antigenic cross-reactivity between SARS-CoV-2 and human tissue with a possible link to an increase in autoimmune diseases. *Clin Immunol*. 2020;217:108480.
40. Ntouros PA, Vlachogiannis NI, Pappa M, Nezos A, Mavragani CP, Tektonidou MG, et al. Effective DNA damage response after acute but not chronic immune challenge: SARS-CoV-2 vaccine versus Systemic Lupus Erythematosus. *Clin Immunol*. 2021;229:108765.
41. Sprent J, King C. COVID-19 vaccine side effects: the positives about feeling bad. *Sci Immunol*. 2021;6:eabj9256.
42. Goldman M, Hermans C. Thrombotic thrombocytopenia associated with COVID-19 infection or vaccination: possible paths to platelet factor 4 autoimmunity. *PLoS Medicine*. 2021;18:e1003648.
43. Mastellos DC, Skendros P, Lambris JD. Is complement the culprit behind COVID-19 vaccine-related adverse reactions? *J Clin Invest*. 2021;131:e151092.
44. Greinacher A, Selleng K, Mayerle J, Palankar R, Wesche J, Reiche S, et al. Anti-platelet factor 4 antibodies causing VITT do not cross-react with SARS-CoV-2 spike protein. *Blood*. 2021;138:1269–77.
45. Risma KA, Edwards KM, Hummell DS, Little FF, Norton AE, Stallings A, et al. Potential mechanisms of anaphylaxis to COVID-19 mRNA vaccines. *J Allergy Clin Immunol*. 2021;147:2075–82 e2.
46. Reinke S, Thakur A, Gartlan C, Bezbradica JS, Milicic A. Inflammasome-mediated immunogenicity of clinical and experimental vaccine adjuvants. *Vaccines*. 2020;8:554.
47. Teijaro JR, Farber DL. COVID-19 vaccines: modes of immune activation and future challenges. *Nat Rev Immunol*. 2021;21:195–7.
48. Li Z, Guo J, Bi L. Role of the NLRP3 inflammasome in autoimmune diseases. *Biomed Pharmacother*. 2020;130:110542.
49. Cabanillas B, Akdis CA, Novak N. Allergic reactions to the first COVID-19 vaccine: a potential role of polyethylene glycol? *Allergy*. 2021;76:1617–8.
50. Krantz MS, Liu Y, Phillips EJ, Stone CA Jr. COVID-19 vaccine anaphylaxis: PEG or not? *Allergy*. 2021;76:1934–7.
51. Borgsteede SD, Geersing TH, Tempels-Pavlica Ž. Other excipients than PEG might cause serious hypersensitivity reactions in COVID-19 vaccines. *Allergy*. 2021;76:1941–2.
52. Ndeupen S, Qin Z, Jacobsen S, Bouteau A, Estantbouli H, Igyarto BZ. The mRNA-LNP platform's lipid nanoparticle component used in preclinical vaccine studies is highly inflammatory. *iScience*. 2021;24:103479.
53. Thaler J, Ay C, Gleixner KV, Hauswirth AW, Cacioppo F, Grafeneder J, et al. Successful treatment of vaccine-induced prothrombotic immune thrombocytopenia (VIPIT). *J Thromb Haemost*. 2021;19:1819–22.
54. Suresh P, Petchey W. ChAdOx1 nCoV-19 vaccine-induced immune thrombotic thrombocytopenia and cerebral venous sinus thrombosis (CVST). *BMJ Case Rep*. 2021;14:e243931.
55. Sørvoll IH, Horvei KD, Ernsten SL, Lægred II, Lund S, Grønli RH, et al. An observational study to identify the prevalence of thrombocytopenia and anti-PF4/polyanion antibodies in Norwegian health care workers after COVID-19 vaccination. *J Thromb Haemost*. 2021;19:1813–8.
56. See I, Su JR, Lale A, Woo EJ, Guh AY, Shimabukuro TT, et al. US Case Reports of Cerebral Venous Sinus Thrombosis With Thrombocytopenia After Ad26.COV2.S Vaccination, March 2 to April 21, 2021. *JAMA*. 2021;325:2448–56.
57. Scully M, Singh D, Lown R, Poles A, Solomon T, Levi M, et al. Pathologic antibodies to platelet factor 4 after ChAdOx1 nCoV-19 vaccination. *N Engl J Med*. 2021;384:2202–11.
58. Schultz NH, Sørvoll IH, Michelsen AE, Munthe LA, Lund-Johansen F, Ahlen MT, et al. Thrombosis and

- thrombocytopenia after ChAdOx1 nCoV-19 vaccination. *N Engl J Med.* 2021;384:2124–30.
59. Greinacher A, Thiele T, Warkentin TE, Weisser K, Kyrle PA, Eichinger S. Thrombotic thrombocytopenia after ChAdOx1 nCoV-19 vaccination. *N Engl J Med.* 2021;384:2092–101.
 60. Guetl K, Gary T, Raggam RB, Schmid J, Wölfler A, Brodmann M. SARS-CoV-2 vaccine-induced immune thrombotic thrombocytopenia treated with immunoglobulin and argatroban. *Lancet.* 2021;397:e19.
 61. Hocking J, Chunilal SD, Chen VM, Brighton T, Nguyen J, Tan J, et al. The first known case of vaccine-induced thrombotic thrombocytopenia in Australia. *Med J Aust.* 2021;215:19–20. e1.
 62. Mehta PR, Apap Mangion S, Bengner M, Stanton BR, Czuprynska J, Arya R, et al. Cerebral venous sinus thrombosis and thrombocytopenia after COVID-19 vaccination - a report of two UK cases. *Brain Behav Immun.* 2021;95:514–7.
 63. Simpson CR, Shi T, Vasileiou E, Katikireddi SV, Kerr S, Moore E, et al. First-dose ChAdOx1 and BNT162b2 COVID-19 vaccines and thrombocytopenic, thromboembolic and hemorrhagic events in Scotland. *Nat Med.* 2021;27:1290–7.
 64. Pottegård A, Lund LC, Karlstad Ø, Dahl J, Andersen M, Hallas J, et al. Arterial events, venous thromboembolism, thrombocytopenia, and bleeding after vaccination with Oxford-AstraZeneca ChAdOx1-S in Denmark and Norway: population based cohort study. *BMJ.* 2021;373:n1114.
 65. Öcal O, Stecher SS, Wildgruber M. Portal vein thrombosis associated with ChAdOx1 nCoV-19 vaccination. *Lancet Gastroenterol Hepatol.* 2021;6:676.
 66. Franchini M, Testa S, Pezzo M, Glingani C, Caruso B, Terenziani I, et al. Cerebral venous thrombosis and thrombocytopenia post-COVID-19 vaccination. *Thromb Res.* 2021;202:182–3.
 67. Bayas A, Menacher M, Christ M, Behrens L, Rank A, Naumann M. Bilateral superior ophthalmic vein thrombosis, ischaemic stroke, and immune thrombocytopenia after ChAdOx1 nCoV-19 vaccination. *Lancet.* 2021;397:e11.
 68. Muster V, Gary T, Raggam RB, Wölfler A, Brodmann M. Pulmonary embolism and thrombocytopenia following ChAdOx1 vaccination. *Lancet.* 2021;397:1842.
 69. Costello A, Pandita A, Devitt J. Case report: thrombotic thrombocytopenia after COVID-19 janssen vaccination. *Am Fam Physician.* 2021;103:646–7.
 70. Muir KL, Kallam A, Koepsell SA, Gundabolu K. Thrombotic Thrombocytopenia after Ad26.COV2.S Vaccination. *N Engl J Med.* 2021;384:1964–5.
 71. Hwang J, Lee SB, Lee SW, Lee MH, Koyanagi AI, Jacob L, et al. Comparison of vaccine-induced thrombotic events between ChAdOx1 nCoV-19 and Ad26.COV2.S vaccines. *J Autoimmun.* 2021;122:102681.
 72. Welsh KJ, Baumblatt J, Chege W, Goud R, Nair N. Thrombocytopenia including immune thrombocytopenia after receipt of mRNA COVID-19 vaccines reported to the Vaccine Adverse Event Reporting System (VAERS). *Vaccine.* 2021;39:3329–32.
 73. King ER, Towner E. A case of immune thrombocytopenia after BNT162b2 mRNA COVID-19 vaccination. *Am J Case Rep.* 2021;22:e931478.
 74. Fueyo-Rodriguez O, Valente-Acosta B, Jimenez-Soto R, Neme-Yunes Y, Inclán-Alarcón SI, Trejo-Gonzalez R, et al. Secondary immune thrombocytopenia supposedly attributable to COVID-19 vaccination. *BMJ Case Rep.* 2021;14:e242220.
 75. Blank M, Barzilai O, Shoenfeld Y. Molecular mimicry and autoimmunity. *Clin Rev Allergy Immunol.* 2007;32:111–8.
 76. Dotan A, Muller S, Kanduc D, David P, Halpert G, Shoenfeld Y. The SARS-CoV-2 as an instrumental trigger of autoimmunity. *Autoimmun Rev.* 2021;20:102792.
 77. Kanduc D, Shoenfeld Y. Molecular mimicry between SARS-CoV-2 spike glycoprotein and mammalian proteomes: implications for the vaccine. *Immunol Res.* 2020;68:310–3.
 78. Oldstone MB. Molecular mimicry and immune-mediated diseases. *FASEB J.* 1998;12:1255–65.
 79. Othman M, Labelle A, Mazzetti I, Elbatarny HS, Lillicrap D. Adenovirus-induced thrombocytopenia: the role of von Willebrand factor and P-selectin in mediating accelerated platelet clearance. *Blood.* 2007;109:2832–9.
 80. Lai KY, Au SY, Fong KM. Thrombotic thrombocytopenia after ChAdOx1 nCoV-19 vaccination. *N Engl J Med.* 2021;385:e11.
 81. Eichinger S, Warkentin TE, Greinacher A. Thrombotic thrombocytopenia after ChAdOx1 nCoV-19 vaccination. Reply *N Engl J Med.* 2021;385:e11.
 82. Ramge P, Unger RE, Oltrogge JB, Zenker D, Begley D, Kreuter J, et al. Polysorbate-80 coating enhances uptake of polybutylcyanoacrylate (PBCA)-nanoparticles by human and bovine primary brain capillary endothelial cells. *Eur J Neurosci.* 2000;12:1931–40.
 83. Choi PY. Thrombotic thrombocytopenia after ChAdOx1 nCoV-19 vaccination. *N Engl J Med.* 2021;385:e11.
 84. Talotta R, Robertson ES. Antiphospholipid antibodies and risk of post-COVID-19 vaccination thrombophilia: the straw that breaks the camel's back? *Cytokine Growth Factor Rev.* 2021;60:52–60.
 85. Lentz SR. Cooling down VITT with IVIG. *Blood.* 2021;138:921–2.
 86. Candelli M, Rossi E, Valletta F, De Stefano V, Franceschi F. Immune thrombocytopenic purpura after SARS-CoV-2 vaccine. *Br J Haematol.* 2021;194:547–9.
 87. Julian JA, Mathern DR, Fernando D. Idiopathic thrombocytopenic purpura and the Moderna Covid-19 vaccine. *Ann Emerg Med.* 2021;77:654–6.
 88. Hines A, Shen JG, Olazagasti C, Shams S. Immune thrombocytopenic purpura and acute liver injury after COVID-19 vaccine. *BMJ Case Rep.* 2021;14:e242678.
 89. Jasaraj RB, Shrestha DB, Gaire S, Kassem M. Immune thrombocytopenic purpura following Pfizer-BioNTech COVID-19 vaccine in an elderly female. *Cureus.* 2021;13:e16871.
 90. Wong JSY, Kang JH, Maw KZ. Acute immune thrombocytopenic purpura post first dose of COVID-19 vaccination. *Postgrad Med J.* 2021. doi:10.1136/postgradmedj-2021-140947
 91. Perricone C, Ceccarelli F, Neshet G, Borella E, Odeh Q, Conti F, et al. Immune thrombocytopenic purpura (ITP) associated with vaccinations: a review of reported cases. *Immunol Res.* 2014;60(2–3):226–35.
 92. Huang C, Xing X, Xiang X, Fan X, Men R, Ye T, et al. MicroRNAs in autoimmune liver diseases: from diagnosis to potential therapeutic targets. *Biomed Pharmacother.* 2020;130:110558.
 93. Liaskou E, Hirschfield GM, Gershwin ME. Mechanisms of tissue injury in autoimmune liver diseases. *Semin Immunopathol.* 2014;36:553–68.

94. Berry PA, Smith-Laing G. Hepatitis A vaccine associated with autoimmune hepatitis. *World J Gastroenterol.* 2007;13:2238–9.
95. Sasaki T, Suzuki Y, Ishida K, Kakisaka K, Abe H, Sugai T, et al. Autoimmune hepatitis following influenza virus vaccination: two case reports. *Medicine.* 2018;97:e11621.
96. Bril F, Al Diffalha S, Dean M, Fettig DM. Autoimmune hepatitis developing after coronavirus disease 2019 (COVID-19) vaccine: Causality or casualty? *J Hepatol.* 2021;75:222–4.
97. Capecchi PL, Lazzerini PE, Brillanti S. Comment on "Autoimmune hepatitis developing after coronavirus disease 2019 (COVID-19) vaccine: Causality or casualty?". *J Hepatol.* 2021;75:994–5.
98. Clayton-Chubb D, Schneider D, Freeman E, Kemp W, Roberts SK. Autoimmune hepatitis developing after the ChAdOx1 nCoV-19 (Oxford-AstraZeneca) vaccine *J Hepatol.* 2021;75:1249–50.
99. Ghielmetti M, Schaufelberger HD, Mieli-Vergani G, Cerny A, Dayer E, Vergani D, et al. Acute autoimmune-like hepatitis with atypical anti-mitochondrial antibody after mRNA COVID-19 vaccination: a novel clinical entity? *J Autoimmun.* 2021;123:102706.
100. Rocco A, Sgamato C, Compare D, Nardone G. Autoimmune hepatitis following SARS-CoV-2 vaccine: may not be a casualty. *J Hepatol.* 2021;75:728–29.
101. McShane C, Kiat C, Rigby J, Crosbie O. The mRNA COVID-19 vaccine - a rare trigger of Autoimmune Hepatitis? *J Hepatol.* 2021;75:1252–4.
102. Londono MC, Gratacos-Gines J, Saez-Penataro J. Another case of autoimmune hepatitis after SARS-CoV-2 vaccination. Still casualty? *J Hepatol.* 2021;75:1248–9.
103. Vuille-Lessard E, Montani M, Bosch J, Semmo N. Autoimmune hepatitis triggered by SARS-CoV-2 vaccination. *J Autoimmun.* 2021;123:102710.
104. Relu M, Jothimani D, Vij M, Rajakumar A, Rammohan A. Autoimmune hepatitis following COVID vaccination. *J Autoimmun.* 2021;123:102688.
105. Leonhard SE, Mandarakas MR, Gondim FAA, Bateman K, Ferreira MLB, Cornblath DR, et al. Diagnosis and management of Guillain-Barre syndrome in ten steps. *Nat Rev Neurol.* 2019;15:671–83.
106. Waheed S, Bayas A, Hindi F, Rizvi Z, Espinosa PS. Neurological complications of COVID-19: guillain-barre syndrome following pfizer COVID-19 Vaccine. *Cureus.* 2021;13:e13426.
107. McKean N, Chircop C. Guillain-Barré syndrome after COVID-19 vaccination. *BMJ Case Rep.* 2021;14:e244125.
108. Hasan T, Khan M, Khan F, Hamza G. Case of Guillain-Barré syndrome following COVID-19 vaccine. *BMJ Case Rep.* 2021;14:e243629.
109. Razok A, Shams A, Almeer A, Zahid M. Post-COVID-19 vaccine Guillain-Barre syndrome; first reported case from Qatar. *Ann Med Surg.* 2021;67:102540.
110. Patel SU, Khurram R, Lakhani A, Quirk B. Guillain-Barre syndrome following the first dose of the chimpanzee adenovirus-vectored COVID-19 vaccine, ChAdOx1. *BMJ Case Rep.* 2021;14:e242956.
111. McKean N, Chircop C. Guillain-Barre syndrome after COVID-19 vaccination. *BMJ Case Rep.* 2021;14:e244125.
112. Allen CM, Ramsamy S, Tarr AW, Tighe PJ, Irving WL, Tanasescu R, et al. Guillain-barre syndrome variant occurring after SARS-CoV-2 vaccination. *Ann Neurol.* 2021;90:315–8.
113. Bonifacio GB, Patel D, Cook S, Purcaru E, Couzins M, Domjan J, et al. Bilateral facial weakness with paraesthesia variant of Guillain-Barré syndrome following Vaxzevria COVID-19 vaccine. *J Neurol Neurosurg Psychiatry.* 2021:327027.
114. Maramattom BV, Krishnan P, Paul R, Padmanabhan S, Cherukudal Vishnu Nampoothiri S, Syed AA, et al. Guillain-Barre syndrome following ChAdOx1-S/nCoV-19 vaccine. *Ann Neurol.* 2021;90:312–4.
115. Woo EJ, Mba-Jonas A, Dimova RB, Alimchandani M, Zinderman CE, Nair N. Association of receipt of the Ad26.COV2.S COVID-19 vaccine with presumptive Guillain-Barré syndrome, February–July 2021. *JAMA.* 2021;326:1606.
116. Garcia-Grimshaw M, Michel-Chavez A, Vera-Zertuche JM, Galnares-Olalde JA, Hernandez-Vanegas LE, Figueroa-Cucurachi M, et al. Guillain-Barre syndrome is infrequent among recipients of the BNT162b2 mRNA COVID-19 vaccine. *Clin Immunol.* 2021;230:108818.
117. Lunn MP, Cornblath DR, Jacobs BC, Querol L, van Doorn PA, Hughes RA, et al. COVID-19 vaccine and Guillain-Barré syndrome: let's not leap to associations. *Brain.* 2021;144:357–60.
118. Abramson M, Mon-Wei YUS, Campbell KN, Chung M, Salem F. IgA nephropathy after SARS-CoV-2 vaccination. *Kidney Med.* 2021;3:860–3.
119. Tan HZ, Tan RY, Choo JCJ, Lim CC, Tan CS, Loh AHL, et al. Is COVID-19 vaccination unmasking glomerulonephritis? *Kidney Int.* 2021;100:469–71.
120. Hanna C, Herrera Hernandez LP, Bu L, Kizilbash S, Najera L, Rheault MN, et al. IgA nephropathy presenting as macroscopic hematuria in 2 pediatric patients after receiving the Pfizer COVID-19 vaccine. *Kidney Int.* 2021;100:705–6.
121. Rahim SEG, Lin JT, Wang JC. A case of gross hematuria and IgA nephropathy flare-up following SARS-CoV-2 vaccination. *Kidney Int.* 2021;100:238.
122. Babamahmoodi F, Saedi M, Alizadeh-Navaei R, Hedayatzadeh-Omran A, Mousavi SA, Ovaize G, et al. Side effects and Immunogenicity following administration of the Sputnik V COVID-19 vaccine in health care workers in Iran. *Sci Rep.* 2021;11:21464.
123. Cherian S, Paul A, Ahmed S, Alias B, Manoj M, Santhosh AK, et al. Safety of the ChAdOx1 nCoV-19 and the BBV152 vaccines in 724 patients with rheumatic diseases: a post-vaccination cross-sectional survey. *Rheumatol Int.* 2021;41:1441–5.
124. Baimukhamedov C. Arthritis of the left elbow joint after vaccination against SARS-CoV-2 infection. *Int J Rheum Dis.* 2021;24:1218–20.
125. An QJ, Qin DA, Pei JX. Reactive arthritis after COVID-19 vaccination. *Hum Vaccin Immunother.* 2021;17:2954–6.
126. Baimukhamedov C, Makhmudov S, Botabekova A. Seropositive rheumatoid arthritis after vaccination against SARS-CoV-2 infection. *Int J Rheum Dis.* 2021;24:1440–1.
127. Ishay Y, Kenig A, Tsemach-Toren T, Amer R, Rubin L, Hershkovitz Y, et al. Autoimmune phenomena following SARS-CoV-2 vaccination. *Int Immunopharmacol.* 2021;99:107970.
128. Vaccines and Related Biological Products Advisory Committee Meeting FDA Briefing Document Moderna COVID-19 Vaccine. 2020.
129. Patil S, Patil A. Systemic lupus erythematosus after COVID-19 vaccination: a case report. *J Cosmet Dermatol.* 2021;20:3103–4.

130. Zavala-Miranda MF, Gonzalez-Ibarra SG, Perez-Arias AA, Uribe-Urbe NO, Mejia-Vilet JM. New onset systemic lupus erythematosus opening as class V lupus nephritis after COVID-19 vaccination. *Kidney Int.* 2021;100:1340–41.
131. Kreuter A, Burmann SN, Burkert B, Oellig F, Michalowitz AL. Transition of cutaneous into systemic lupus erythematosus following adenoviral vector-based SARS-CoV-2 vaccination. *J Eur Acad Dermatol Venereol.* 2021;35:e733–e5.
132. Vera-Lastra O, Navarro AO, Domiguez MPC, Medina G, Valadez TIS, Jara LJ. Two cases of graves' disease following SARS-CoV-2 vaccination: an autoimmune/inflammatory syndrome induced by adjuvants. *Thyroid.* 2021;31:1436–9.
133. Pierman G, Delgrange E, Jonas C. Recurrence of graves' disease (a th1-type cytokine disease) following SARS-CoV-2 mRNA vaccine administration: a simple coincidence? *Eur J Case Rep Int Med.* 2021;8:002807.
134. Patrizio A, Ferrari SM, Antonelli A, Fallahi P. A case of Graves' disease and type 1 diabetes mellitus following SARS-CoV-2 vaccination. *J Autoimmun.* 2021;125:102738.

How to cite this article: Chen Y, Xu Z, Wang P, Li X-M, Shuai Z-W, Ye D-Q, et al. New-onset autoimmune phenomena post-COVID-19 vaccination. *Immunology.* 2022;165:386–401. <https://doi.org/10.1111/imm.13443>